

Left Brachiocephalic Vessel Venous Tumor Thrombus in a Laryngeal Cancer Patient Detected with PET-CT Imaging

Pelin Ozcan Kara^{1,*}, Zehra Pinar Koc¹, Mesut Sabri Tezer², Taylan Kara³

¹Mersin University, Faculty of Medicine, Department of Nuclear Medicine, Mersin, Turkey

²Mersin University, Faculty of Medicine, Department of Otorhinolaryngology, Mersin, Turkey

³Mersin University, Faculty of Medicine, Department of Radiology, Mersin, Turkey

Abstract:

Accurate diagnosis of tumor thrombus and distinguishing benign thrombus from tumor thrombus avoid unnecessary anticoagulant treatment of oncological patients and it is important for patient management. In this case report, the role of FDG PET/CT in the presentation of a suspicious tumor thrombus in the left brachiocephalic vein of a patient with known laryngeal carcinoma and leiomyosarcoma diagnosis is presented.

Corresponding Author: Pelin Ozcan Kara, Mersin University, Faculty of Medicine, Department of Nuclear Medicine, Mersin, Turkey

Key words: Laryngeal cancer; tumor thrombus; FDG PET-CT

Received Date: June 19, 2017;

Accepted Date: July 17, 2017;

Published Date: Aug 22, 2017

Introduction:

Thrombosis because of venous thromboembolism (VTE) or tumor thrombosis (TT) is generally more common in oncological patients compared with nononcological patients. Tumor thrombus is a very rare but serious complication of solid tumors. Differential diagnosis is mostly difficult with radiological modalities such as ultrasonography (US), magnetic resonance imaging (MRI) and diagnostic computed tomography (CT). There are a few reports on the role of Fluorodeoxyglucose (FDG)-Positron Emission Tomography/Computed Tomography (PET-CT) in the demonstration of rare tumor thrombus in literature. In this case report, the role of FDG PET-CT in the presentation of a suspicious tumor thrombus in the left brachiocephalic vein of a patient with known laryngeal carcinoma and leiomyosarcoma diagnosis is presented.

Case Report:

Discussion: The incidence of thrombus is high in patients with underlying malignancy. This thrombus is mostly venous thromboembolism (VTE), but it may rarely be a tumor thrombus (TT). VTE is common in oncologic patients and is treated with anticoagulant treatment agents whereas aggressive treatment approaches are needed in TT. TT may occur in any cancer and has been reported in many different malignancies (ie, solid carcinomas, sarcomas, and hematologic malignancies) with RCC and HCC being considered the most common underlying malignancies (1). In literature, there is only retrospective few articles

and some case reports on the role of FDG PET-CT imaging (2-6). The FDG uptake pattern in TT is not yet as conclusively established, but generally, a linear FDG uptake pattern or more focal FDG accumulation has been reported in literature (2-6). In a recent interesting image report from Sonavane SN et al, the authors reported the imaging findings of a patient with RCC where PET/CT not only ruled out locoregional adenopathy and distant metastases, but also distinguished tumor thrombi from benign thrombi in the same patient (7). Incidental detection of secondary malignancies or occult metastases from primary malignant disease on 18F-FDG PET/CT has been reported previously (8-10). In this case report, FDG PET-CT imaging was very useful for diagnosis of tumor

thrombus in a patient that diagnostic CT scan could not distinguish tumor thrombus & venous thrombus (Figure 1 A-F).

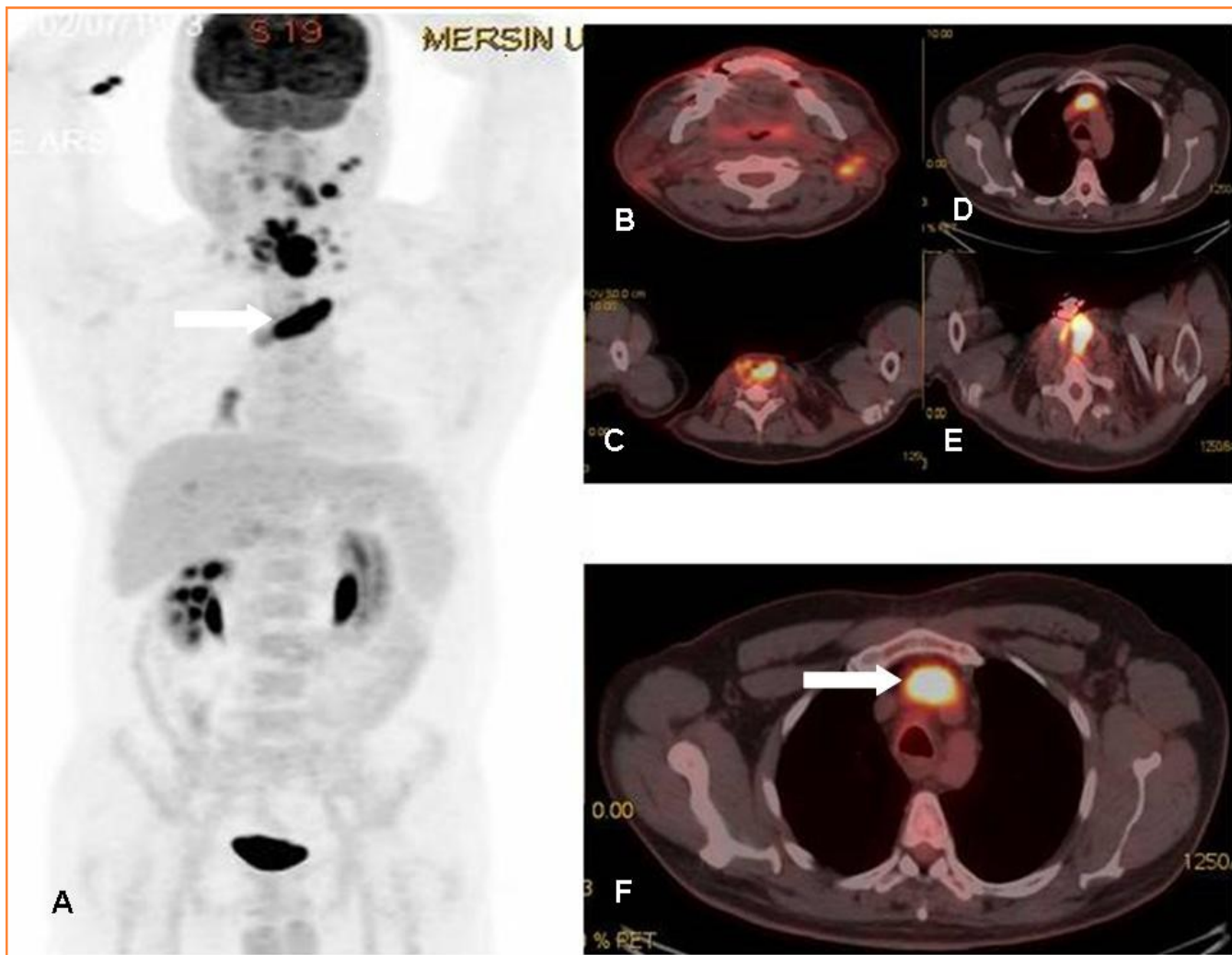


Figure 1: MIP (Maximum intensity Projection-A) and axial PET-CT fusion (B-F) images demonstrate recurrent mass lesion, metastatic lymphadenopathies and tumor thrombus (white arrows).

References

1. Aurangabadkar HU, Palle L, Ali Z. Tumour thrombosis and patterns of fluorine-18 fluorodeoxyglucose uptake: a pictorial review. *Nucl Med Commun.* 2013;34:627-637.
2. Davidson T, Goitein O, Avigdor A, et al. 18F-FDG-PET/CT for the diagnosis of tumor thrombosis. *Isr Med Assoc J.* 2009;11:69-73.
3. Lai P, Bomanji JB, Mahmood S, et al. Detection of tumour thrombus by 18FFDG-PET/CT imaging. *Eur J Cancer Prev.* 2007;16:90-94.
4. Lee EY, Khong PL. The value of 18F-FDG PET/contrast-enhanced CT in detection of tumor thrombus. *Clin Nucl Med.* 2013;38:60-65.
5. Sharma P, Kumar R, Jeph S, et al. 18F-FDG PET-CT in the diagnosis of tumor thrombus: can it be differentiated from benign thrombus? *Nucl Med Commun.* 2011;32:782-788.
6. Ravina M, Hess S, Chauhan MS, Jacob MJ, Abass Alavi A. Tumor Thrombus. Ancillary Findings on FDG PET/CT in an Oncologic Population. *Clin Nucl Med.* 2014;39: 767-771
7. Sonavane SN, Malhotra G, Asopa R, Upadhye T. Role of fluorine-18 fluorodeoxyglucose positron emission tomography in a case of renal cell carcinoma to differentiate tumor thrombus from bland thrombus. *Indian J Nucl Med.* 2015 Oct-Dec;30(4):355-7.
8. Yang J, Zhen L, Zhuang H. Bone marrow metastases from alveolar rhabdomyosarcoma with impressive FDG PET/CT finding but less-revealing bone scintigraphy. *Clin Nucl Med.* 2013 Dec;38 (12):988-91.
9. Yuan L, Kan Y, Meeks JK, et al. 18F-FDG PET/CT for identifying the potential causes and extent of secondary hemophagocytic lymphohistiocytosis. *Diagn Interv Radiol.* 2016;22(5):471-475.
10. Hao R, Yuan L, Kan Y, et al. Diagnostic performance of 18F-FDG PET/CT in patients with fever of unknown origin: a meta-analysis. *Nucl Med Commun.* 2013;34(7):682-688.