

Occlusal Contact Prints; A Biometric Means for Identification

Philip L. Millstein^{1,*}, Carlos E. Sabrosa²

¹DMD, MS. Lecturer at Harvard School of Dental Medicine Department of Restorative Dentistry. Boston, Massachusetts. 02115

²Department of Integrated Procedures, University of the State of Rio de Janeiro, Rio de Janeiro, Brazil

Corresponding author:

Philip L. Millstein, DMD, MS. Lecturer at Harvard School of Dental Medicine Department of Restorative Dentistry. Boston, Massachusetts. 02115

Keywords:

Occlusion, Contacts, Silicone, Light, Camera.

Received: Apr 06, 2022

Accepted: Aug 03, 2022

Published: Aug 05, 2022

Editor:

Brian Muzyka, Hospital Dentistry, 600 Moye Blvd, USA

Abstract

Fingerprints are commonly used for identification [1]. All records are computerized. In a catastrophe recorded images of soft tissue may become useless if the tissues burn throughout.

Dental prints are rarely used for identification. Information is taken from dental radiographs or dental casts. In case of fire recorded images of dental structures may be useful because they do not readily burn.

Introduction

Fingerprints are commonly used for identification [1]. All records are computerized. In a

catastrophe recorded images of soft tissue may become useless if the tissues burn throughout.

Dental prints are rarely used for identification. Information is taken from dental radiographs or dental casts. In case of fire recorded images of dental structures may be useful because they do not readily burn.

Method

Fingerprint records include fingerprint cards along with history and information. No two fingerprints are the same; twins included. Fingerprints are characterized by assessing epidermal and dermal whorls which vary in shape and visual patterns.

Forensic occlusal contact records include individual and collective tooth prints. A dental print is a composite impression of the upper and lower teeth making tooth contact but what makes it unique is that it includes the profile of tooth contours, tooth position and occlusal contact forms of the opposing teeth. Radiographs are two dimensional and flat sided so only profile views of the front, back, and top side can be used for identification purposes. They provide a standard means for crown and root identification. Bite marks do not record the occlusion; however, their anatomy may be compared to radiographs and dental prints. No two occlusal contact prints are of

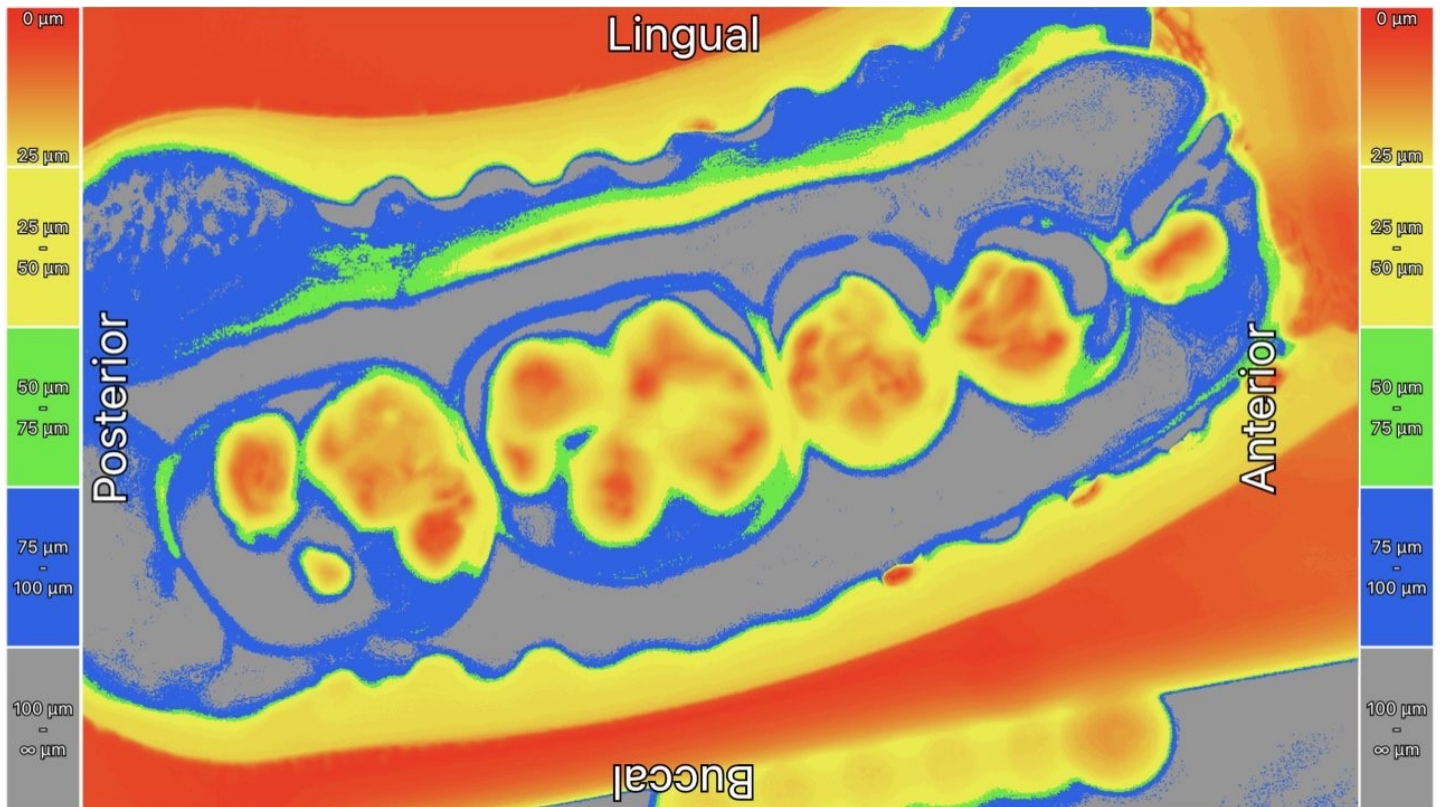


Figure 1. Illuminated occlusal contacts in a segmental arch.

the same size or shape [2,3]. Dental radiographs do not mimic occlusal contact areas nor do dental casts.

Dental prints are made by taking a dental impression in a suitable double arch tray using an instant translucent silicone material [4,5,6]. A standard light box and phone/ camera are used to permanently record the image. The time for making the permanent recordings is two minutes: The cost is minimal. Light transmitted through the translucent impression material makes the identification system possible (Figure 1) by displaying occlusal contact areas, tooth contours, tooth positions, and arch forms. Segmental arch form impressions are quick and easy to render.

Discussion

Dental occlusal contact occurs with the matching of one jaw to another in a closed position. Occlusal contact prints are located between the opposing maxillary and mandibular dental arches when closed. The resulting image is a composite of the occlusal contact areas of the opposing jaws and the surrounding dentitions. Impression

making like fingerprinting must be done by a professional and the results must be analyzed by a professional. Dental impressions are taken in a dental clinic. Dental personnel can be trained to make suitable impressions and to store the data. As with fingerprinting impression making must be precise. [7] An investigator can identify jaw and tooth contours without analyzing tooth contacts. A dentist can identify tooth contacts and tooth rubbings by interpreting occlusal surfaces which represent occlusal contact and grinding areas. No two occlusal contacts or dental articulations are alike. Dental impression systems for identification employ thermoplastic materials and are used for children [8,9]. The plastic impression is stored in a small box. The new instant impression system is primarily used for adults. The results are photographed and made internet available. The impression is discarded.

Summary

No two occlusal recordings including those of twins are the same. Dental impressions differ among individuals and can be used for identification. Fingerprints are the standard method for identification. This system is

additive to fingerprinting and may provide adjunctive information.

References

1. Federal Bureau of Investigation. Quantico, Virginia
2. Millstein PL. An Evaluation of Occlusal Contact Marking Indicators: A Descriptive Qualitative Method. Quintessence International. 8:813-818, 1983
3. Millstein PL; An Evaluation of Occlusal Indicator Wax. J Prosthet Dent. 1985;53:570.
4. Hahn SM, Millstein PL, Kinnunen MA, Wright RF. The Effect of Impression Volume and Double Arch Trays on The Registration of Maximum Intercuspatation. J Prosthet Dent. 2009; 102: 362-36
5. Millstein PL, Sabrosa CE, Florencio S, Geber K. Consistency and Repeatability of Digitized Occlusal Records. URRD, 2020; 3 (2): 24-29.
6. Millstein PL, Sabrosa CE, Yung Wai, Geber K. Occlusal Contacts for Implant Dentistry. OHDM, 2021; 20 No.6: 1-2.
7. Samet, M, Shohat, M, Livni, M, et al. A Clinical evaluation of fixed partial denture impressions J Prosthet Dent. 2005; 94: 112-17.
8. Promotion of the Use of a Thermoplastic Material to Aid in the Identification of Unidentified Human Remains. American Board Of Forensic Odontology Position Paper. Journal of The Massachusetts Dental Society. 2005; 54 (2): 14-16.
9. Tesini, DA. Support for the Use of Thermoplastic Bite Impressions to Aid in the Identification of Missing and Unknown Children. Journal of the Massachusetts Dental Society. 2005; 54: 16-19.